

See discussions, stats, and author profiles for this publication at: <https://www.researchgate.net/publication/264298692>

# Changes in 3D Midfacial Parameters after Biomimetic Oral Appliance Therapy in Adults

Article in *The Journal of Indian Orthodontic Society* · March 2014

DOI: 10.5005/jip-journals-10021-1226

---

CITATIONS

12

---

READS

168

3 authors, including:



Prof. G. Dave Singh

Vivos Therapeutics, Inc.

105 PUBLICATIONS 1,369 CITATIONS

SEE PROFILE

Some of the authors of this publication are also working on these related projects:



3D technologies in the diagnosis and management of OSA [View project](#)

# Changes in 3D Midfacial Parameters after Biomimetic Oral Appliance Therapy in Adults

<sup>1</sup>G Dave Singh, <sup>2</sup>Tammarie Heit, <sup>3</sup>Derek Preble

## ABSTRACT

**Background/objectives/aims:** Controversy exists regarding maxillary bone changes in nongrowing adults. However, previous studies have relied on two-dimensional (2D) cephalometric analyses, which may be unable to capture three-dimensional (3D) phenomena. In this study, we investigated 2D and 3D parameters to test the null hypothesis that maxillary bone volume cannot be changed in nongrowing adults that had been diagnosed with midfacial underdevelopment.

**Methods:** After obtaining informed consent, we undertook 3D cone beam computed tomography scans of 11 consecutive, adult patients prior to and after biomimetic, oral appliance therapy. The mean treatment time was 18.4 months  $\pm$  2.5 using the DNA appliance<sup>®</sup> system. The intramolar width and 3D volume of the midface was calculated prior to and after the midfacial redevelopment protocol. The findings were subjected to statistical analysis.

**Results:** The mean intramolar increased from 33.5 mm  $\pm$  3.4 prior to treatment to 35.8 mm  $\pm$  2.9 after appliance therapy ( $p = 0.0003$ ). Similarly, the mean midfacial bone volume was 17.4 cm<sup>3</sup>  $\pm$  3.9 prior to treatment and increased to 19.1 cm<sup>3</sup>  $\pm$  2.6 after appliance therapy ( $p = 0.0091$ ).

**Conclusion:** These data support the notion that maxillary bone width and volume can be changed in nongrowing adults. Furthermore, midfacial redevelopment may provide a potentially-useful method of managing adults diagnosed with obstructive sleep apnea, using biomimetic, oral appliances.

**Keywords:** Maxillary expansion, Palatal expansion, Adult, Biomimetic appliance.

**How to cite this article:** Singh GD, Heit T, Preble D. Changes in 3D Midfacial Parameters after Biomimetic Oral Appliance Therapy in Adults. *J Ind Orthod Soc* 2014;48(2):104-108.

**Source of support:** Nil

**Conflict of interest:** Professor Singh is CEO of BioModeling Solutions, Inc.

<sup>1</sup>CEO, <sup>2,3</sup>Owner

<sup>1</sup>BioModeling Solutions, Inc., Cornell Oaks Corporate Center Beaverton, Oregon, USA

<sup>2</sup>Scotia Square Dentistry, Edmonton, Alberta, Canada

<sup>3</sup>C Inside, Salt Lake City, Utah, USA

**Corresponding Author:** G Dave Singh, BioModeling Solutions Inc., Cornell Oaks Corporate Center, 15455 NW Greenbrier Parkway, Commons Building, Suite 250, Beaverton, Oregon 97006, USA, Phone: +1 (503) 430-7529/7536, Fax: +1 (866) 201-3869, e-mail: drsingh@drdavesingh.com

Received on: 27/6/13

Accepted after Revision: 12/1/14

## INTRODUCTION

Recent advances in imaging techniques permit the visualization of clinical craniofacial structures in three-dimensional (3D) using advanced imaging and data acquisition techniques.<sup>1</sup> Some of these 3D techniques can be used for modeling clinical data, unlike previous two-dimensional (2D) cephalometric analyses. Singh et al<sup>2</sup> reviewed various 3D imaging and modeling techniques that may provide new insights into both surgical and nonsurgical clinical interventions. Generic methods are commonly used for modeling purposes with computed tomography (CT) image (DICOM) format, mesh format (STL), and so on; these data can be superimposed over time or used to derive 3D mean configurations that can be interrogated statistically.<sup>3</sup>

Regarding the maxilla, Gracco et al<sup>4</sup> evaluated volumetric variations in the palate following rapid maxillary expansion in children, noting that the volume of the palate increased. But, controversy exists in literature regarding the extent to which maxillary bone parameters can be changed in nongrowing adults. However, previous studies in adults have relied on 2D cephalometric analysis, which may be unable to capture 3D phenomena.<sup>5</sup> Nevertheless, using computer-assisted, pre- and postoperative evaluations of surgically-assisted, rapid maxillary expansion in adults, Kober et al<sup>6</sup> reported that while the maxilla was found to widen, the results indicated a decrease in bone quality in those adults. Therefore, the aim of this study is to investigate 2D and 3D changes in maxillary bone parameters following a nonsurgical, midfacial development protocol, and to test the null hypothesis that maxillary bone volume cannot be changed in nongrowing adults diagnosed with midfacial underdevelopment.

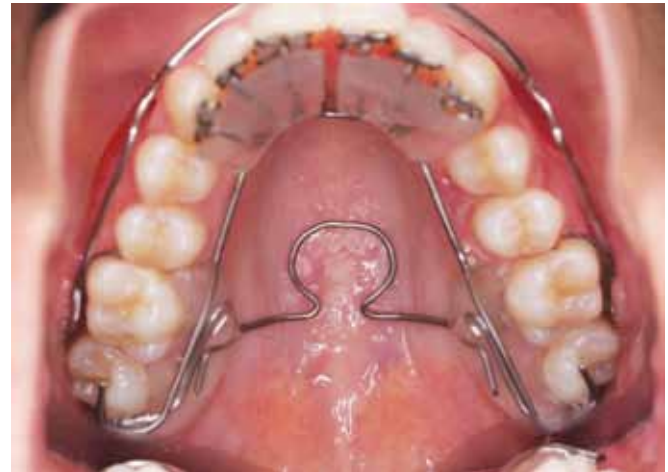## MATERIALS AND METHODS

After obtaining informed consent, 13 consecutive patients were recruited for this study. The rights of the subjects were protected by following the Declaration of Helsinki. Inclusion criteria were adults over age 21 years diagnosed with clinical, midfacial underdevelopment (such as a narrow palate or posterior crossbite); good compliance; no history

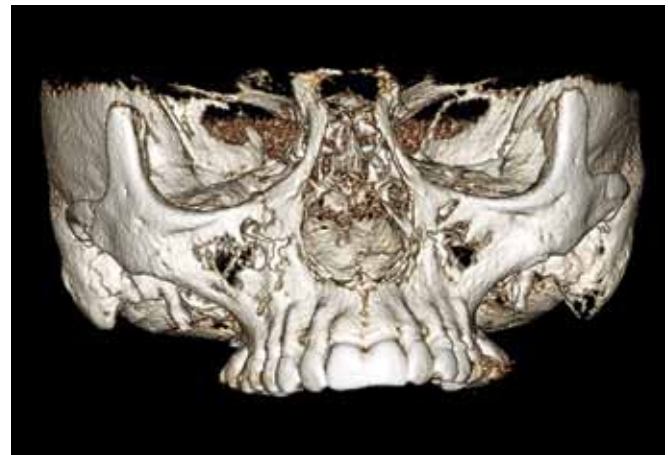of hospitalization for craniofacial trauma or surgery; no congenital, craniofacial anomalies, and a fully-dentate upper arch. The exclusion criteria included: age <21 years; lack of compliance; active periodontal disease; tooth loss during treatment; poor oral hygiene, and systemic bisphosphonate therapy. After careful history-taking and craniofacial examination, we undertook 3D cone-beam computerized axial tomographic (3D CBCT) scans using an iCAT CBCT machine (Imaging Sciences International, Hatfield, PA). Strict positioning protocols were used and a 20 seconds scan was performed using a wide (13 cm) field of view.

A neuromuscular bite registration was obtained in the upright-sitting position with corrected jaw posture in the vertical axis specific for each subject. Upper and lower polyvinylsiloxane impressions were also obtained. The upper model was then mounted using the hammular notch-incisive papilla plane method on a Stratos articulator (Ivoclar-Vivadent, Amherst, New York, USA), and the lower model was mounted relative to the upper model, using the bite registration captured in the physiologic rest position.

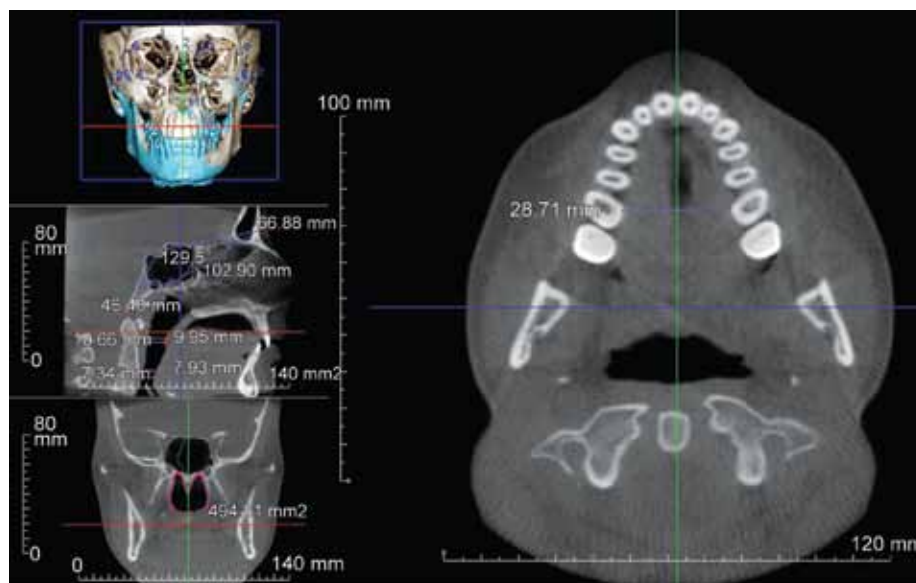
Following diagnostics, a biomimetic, upper DNA appliance<sup>7-13</sup> (Fig. 1) was prescribed for each subject. The DNA appliance system is designed to correct maxillomandibular underdevelopment in both children and adults. The wireframe DNA appliance used in this study had six (patented) anterior 3D axial springs<sup>TM</sup>, midline anterior and posterior omega loops, posterior occlusal stop, retentive clasps, and a labial bow (see Fig. 1). All subjects were instructed to wear the DNA appliance during the late afternoon, early evening and at night time (for approx. 10-12 hrs in total), but not during the day time and not while eating, partly in line with the circadian rhythm of tooth eruption,<sup>14</sup> although this only



**Fig. 1:** The wireframe DNA appliance design used in this case, which incorporates midline anterior and posterior omega loops, three-dimensional axial springs<sup>TM</sup>, Adam's clasps, occlusal stops and a labial bow

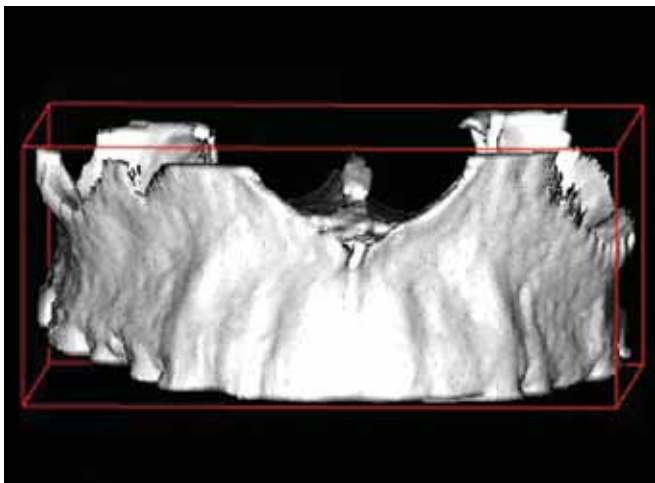


**Fig. 2:** For volumetric reconstruction of the craniomaxillary region, appropriate software was implemented and midfacial reconstruction was undertaken prior to further processing for measurement purposes



**Fig. 3:** Axial two-dimensional image from a three-dimensional cone beam computed tomography scan showing the minimum intramolar width measurement at the cervical margin of the mesiopalatal cusp of the first molar. This bone width was measured prior to and after the midfacial redevelopment protocol



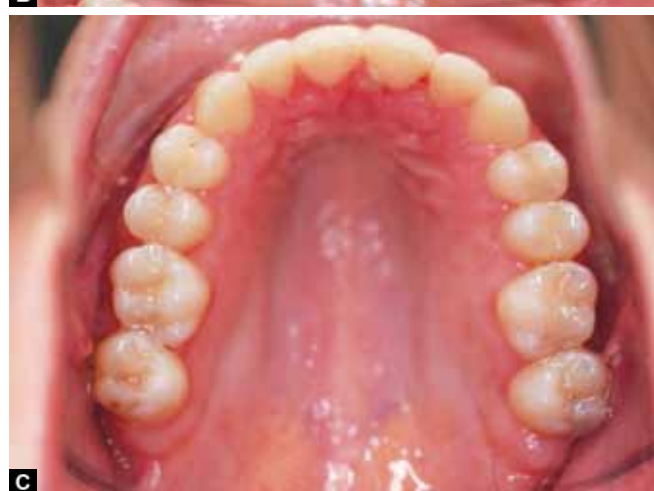
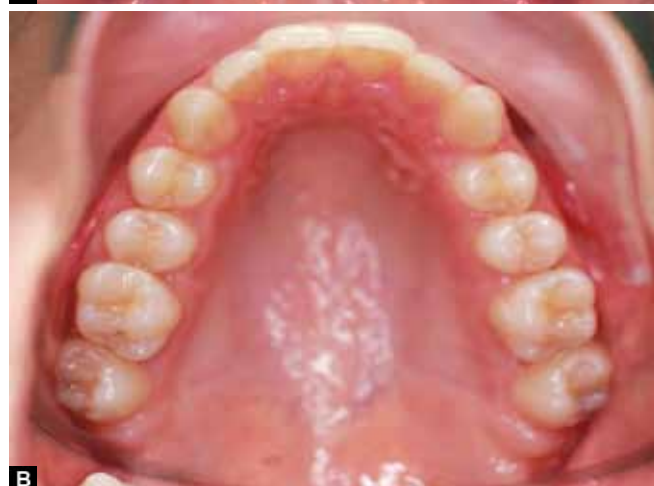
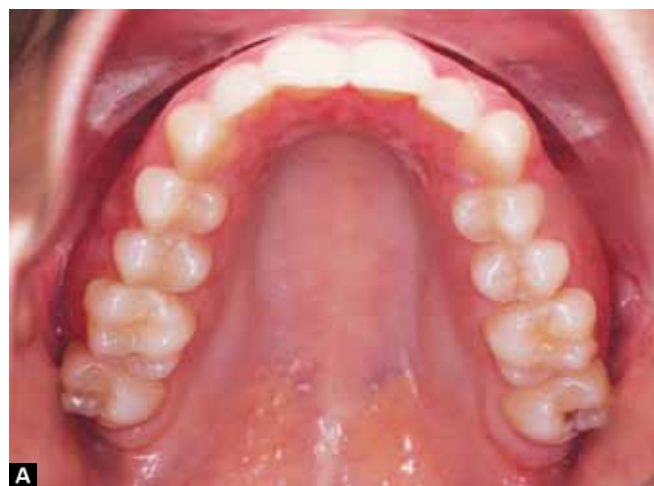**Fig. 4:** A midfacial reconstruction that has been segmented between the anterior and posterior nasal spines, the dentoalveolar margin and the hard palate, including the palatine bone, but excluding the frontal process of the maxilla and the crowns of the teeth for volumetric measurement. This bone volume was measured prior to and after the midfacial redevelopment protocol

occurs in children. The appliance was adjusted every 4 weeks approximately. The subjects were also instructed on how to perform an orofacial myofunctional exercise (the ‘zygoma lift’)<sup>15</sup> and had to demonstrate successful implementation of the exercise routine prior to discharge. Written and verbal instructions were given to all subjects.

All subjects reported for review each month. At each monthly follow-up, examination for the progress of midfacial development was recorded. Adjustments to the devices were performed to optimize their efficacy. Only gentle pressures were transmitted to the teeth and the functionality of the device was checked with the subject activating a mild force on biting. The subjects were encouraged to maintain their treatment regimen as outlined at the outset. Development of the lower arch was implemented using a lower appliance to permit arch recoordination. A lower appliance was implemented between 6 and 12 months depending on the patient’s progress.

For volumetric reconstruction of the midface (Fig. 2), appropriate software was implemented (Anatomage, inVivo Dental, San Jose, CA, USA). The minimum intramolar width at the cervical margin of the mesiopalatal cusp of the first molar was measured prior to and after the midfacial redevelopment protocol (Fig. 3). The 2D measurement protocol was repeated three times to determine the percentage measurement error. Next, midface segmentation was undertaken between the anterior and posterior nasal spines, the dentoalveolar margin and the hard palate, including the palatine bone, but excluding the frontal process of the maxilla and the crowns of the teeth (Fig. 4). In addition, the bony 3D volume of the midface, excluding the frontal process of the maxilla, was computed in all cases. The 3D measurement protocol was also repeated three times to determine the



**Figs 5A to C:** An example of midfacial development in one of the subjects that participated in this study: (A) Pretreatment presentation, (B) the progress of midfacial development, (C) The outcome in this particular example, in which the palatal bone width appears to have increased

percentage measurement error. At 18 months, these data measurements were repeated and the findings were subjected to statistical analysis, using t-tests.

## RESULTS

Two subjects were excluded from the study; one subject did not meet the age criteria for inclusion and one subject

had maxillary third molars removed during the active phase of treatment. Figures 5A to C show an example of midfacial development in one of the remaining 11 subjects that participated in this study. Figure 5A is the pretreatment presentation. Figure 5B shows the progress of midfacial development. Figure 5C shows the outcome in this particular example, in which the palatal bone width appears to have increased. Indeed, for the entire sample, the mean, minimum intramolar width (*see* Fig. 3) was found to be 33.5 mm ± 3.4 prior to treatment. This bone width increased to 35.8 mm ± 2.9 after appliance therapy (p = 0.0003). For 2D measurements, the error was found to be 0.79%. Therefore, further analyses were warranted. For the entire sample, the mean, midfacial bone volume was 17.4 cm<sup>3</sup> ± 3.9 prior to treatment. The midfacial bone volume increased to 19.1cm<sup>3</sup> ± 2.6 after appliance therapy (p = 0.0091). The 3D measurement error was found to be 0.92%. In addition, no instances of palatal or buccal dehiscence or fenestration were found in association with any of the tooth roots in any of the subjects (*see* Fig. 4). These results are summarized in Tables 1 and 2 and Figures 3 to 5A to C.

**Table 1:** List of minimum intramolar widths pre- and post-treatment. The mean, minimum intramolar width increased from 33.5 to 35.8 mm after biomimetic oral appliance therapy

Subject	Pretreatment width (mm)	Posttreatment width (mm)
ASE	28.71	34.7
FE	31.12	33.29
HF	33.44	35.75
CH	32.95	36.64
KH	35.44	37.03
NN	30.12	31.88
KR	32.57	32.95
JD	39.91	42.16
AT	33.89	35.11
TR	38.47	39.19
EA	31.66	34.93
Mean	33.48	35.78

**Table 2:** List of midfacial bone volume pre- and post-treatment. The mean midfacial bone volume increased from 17.4 to 19.1 cm<sup>3</sup> after biomimetic oral appliance therapy

Subject	Pre-treatment volume mm <sup>3</sup>	Post-treatment volume mm <sup>3</sup>
ASE	14143	15121
FE	15218	19823
HF	19374	21289
CH	20036	20609
KH	18884	19572
NN	16689	16869
KR	12389	17287
JD	21536	21858
EA	22146	22085
TR	20971	21044
AT	10402	15264
Mean	17435.3	19165.5

## DISCUSSION

Volumetric measurements from 3D CBCT scan data must be done with due diligence employing a good technique, as the measurement values may change according to the image threshold value chosen. In order to prevent this type of error, the same image threshold value was used for each specific patient. In addition, the amount of imaging artifacts and digital ‘noise’ varies with each CBCT machine used and for each patient, which may also affect the volume measurements. Therefore, in order to prevent this type of error, the same CBCT machine was used for all subjects in this study. Indeed, following these guidelines, the percentage error for replicate 2D and 3D measurements was found to be 0.79 and 0.92%, respectively. Therefore, the results of the measurement protocol used in this investigation were deemed to be acceptable. Fuyamada et al<sup>16</sup> compared the reproducibility of landmark identification in 3D CBCT images. Significant differences were not found as long as strict definitions were employed, as in this present study. Thus, using 3D CBCT data Gracco et al<sup>4</sup> undertook volumetric reconstruction of the palate following rapid maxillary expansion in children in the mixed dentition. As expected, the volume of the palate increased. For the management of obstructive sleep apnea (OSA) in children, Marino et al<sup>17</sup> evaluated the effects of rapid maxillary expansion (RME). They surmised that young children with bimaxillary retrognathia could benefit from RME. However, doubt exists whether midfacial development can be performed in adults for the correction of OSA. Therefore, the aim of this study was to test the null hypothesis that maxillary bone volume cannot be changed in nongrowing adults that had been diagnosed with midfacial underdevelopment, as midfacial underdevelopment is associated with OSA in adults.<sup>18</sup>

For adults, Nair et al<sup>19</sup> undertook quantitative analysis of the maxilla in skeletal Class II cases. No significant differences were found between the volumes of the maxilla (although differences were reported in the ratio of maxillo-mandibular volume). Thus, one objective of this present study was to determine whether a biomimetic appliance protocol has the ability to invoke new bone formation in nongrowing adults. Biomimetics is a science that uses natural designs or mechanisms to solve human problems. In this case, the intention is to accommodate 16 teeth in the maxilla to correct features of malocclusion, such as crowding, posterior crossbite, and so on. It is postulated that adults retain the capacity to regenerate and remodel bone at the craniofacial sutures.<sup>20</sup> Indeed, Ferguson et al<sup>21</sup> state that the genetic mechanisms that invoke bone formation *de novo* in fetuses are the same as those that permit new bone formation in adult skeletal fractures. Thus, it is feasible that new (woven) bone might be laid down to maintain

sutural homeostasis. Preliminary evidence for this notion is provided by Singh and Krumholtz<sup>15</sup> that illustrates a bone biopsy taken from an adult dentition subjected to ultra-light dentoalveolar tensile stresses. Indeed, Mao and Nah<sup>22</sup> show that tensile stresses upregulate BMP4 gene expression in mouse cranial sutures. Therefore, it is plausible that, because of homology, mammalian developmental mechanism(s) responsible for new bone formation might be amenable to reactivation in adults undergoing biomimetic appliance therapy. In fact, our initial data appear to support the notion that maxillary bone width and volume can be changed in nongrowing adults. Furthermore, in other studies, Singh et al;<sup>7</sup> Singh and Cress,<sup>10</sup> and Singh and Callister<sup>23</sup> showed that increased maxillary bone parameters are associated with increased upper airway volume concomitant with a decreased apnea-hypopnea index (AHI) in nongrowing adults. Therefore, midfacial redevelopment may provide a potentially useful method of addressing an elevated AHI, by using biomimetic oral appliances in adults diagnosed with OSA. Despite these contentions, further large-scale studies and randomized clinical trials are needed. In addition, the results of this present study need to be viewed with caution as the long-term stability of volumetric increases in adult bone volume require further determination.

## REFERENCES

1. Enciso R, Memon A, Mah J. Three-dimensional visualization of the craniofacial patient: volume segmentation, data integration and animation. *Orthod Craniofac Res* 2003;6:66-71.
2. Singh GD. Digital diagnostics: Three-dimensional modelling. *Br J Oral Maxillofac Surg* 2008;46:22-26.
3. Singh GD, Levy-Bercowski D, Yañez MA, Santiago PE. Three-dimensional facial morphology following surgical repair of unilateral cleft lip and palate in patients after nasoalveolar molding. *Orthod Craniofac Res* 2007;10:161-166.
4. Gracco A, Malaguti A, Lombardo L, Mazzoli A, Raffaelli R. Palatal volume following rapid maxillary expansion in mixed dentition. *Angle Orthod* 2010;80:153-159.
5. Moyers RE, Bookstein FL. The inappropriateness of conventional cephalometrics. *Am J Orthod* 1979;75:599-617.
6. Kober C, Kannenberg S, Frank B, Al-Hakim G, Parvin A, Landes C, Sader R. Computer-assisted pre- and postoperative evaluation of surgically assisted rapid maxillary expansion. *Int J Comput Dent* 2011;14:233-241.
7. Singh GD, Wendling S, Chandrashekhar R. Midfacial development in adult obstructive sleep apnea. *Dent Today* 2011;30:124-127.
8. Singh GD, Utama J. Effect of the DNA appliance<sup>TM</sup> on migraine headache: case report. *Int J Orthod* 2013;24:45-49.
9. Singh GD, Harris WG. Resolution of 'gummy smile' and anterior open bite using the DNA appliance<sup>®</sup>: case report. *J Amer Orthod Soc* 2013;30-34 (in press).
10. Singh GD, Cress SE. Case presentation: effect of full mouth rehabilitation and oral appliance therapy on obstructive sleep apnea. *Dialogue* 2013;2:18-20.
11. Singh GD, Lipka G. Case report: introducing the wireframe DNA appliance<sup>TM</sup>. *J Am Acad Gnathol Orthop* 2009;26(4):8-11.
12. Singh GD, Ataii P. Combined DNA appliance<sup>TM</sup> and Invisalign<sup>TM</sup> therapy without interproximal reduction: a preliminary case series. *J Clin Case Rep* 2013;3(5):271-272.
13. Singh GD, Cress SE. Craniofacial enhancement using a biomimetic oral appliance: case report. *Dent Today* 2013;329(12):92-94.
14. Proffit WR, Frazier-Bowers SA. Mechanism and control of tooth eruption: overview and clinical implications. *Orthod Craniofac Res* 2009;12:59-66.
15. Singh GD, Krumholtz JA. Epigenetic orthodontics in adults. Chatsworth: Appliance Therapy Group 2009:155-156.
16. Fuyamada M, Nawa H, Shibata M, Yoshida K, Kise Y, Katsumata A, Ariji E, Goto S. Reproducibility of landmark identification in the jaw and teeth on 3-dimensional cone-beam computed tomography images. *Angle Orthod* 2011;81:843-849.
17. Marino A, Ranieri R, Chiarotti F, Villa MP, Malagola C: rapid maxillary expansion in children with obstructive sleep apnoea syndrome (OSAS). *Eur J Paediatr Dent* 2012;13:57-63.
18. Banabilh SM, Suzina AH, Dinsuhaimi S, Samsudin AR, Singh GD. Dental arch morphology in South East Asian adults with obstructive sleep apnoea: Geometric morphometrics. *J Oral Rehab* 2009;36:184-192.
19. Nair R, Deguchi TS, Li X, Katashiba S, Chan YH. Quantitative analysis of the maxilla and the mandible in hyper- and hypodivergent skeletal Class II pattern. *Orthod Craniofac Res* 2009;12:9-13.
20. Kokich V. The biology of sutures. In: Cohen MJ, editor. *Cranio-synostosis: diagnosis, evaluation and management*. New York: Raven Press, 1986; Chapter 4.
21. Ferguson C, Alpern E, Miclau T, Helms JA. Does adult fracture repair recapitulate embryonic skeletal formation? *Mech Dev* 1999;87:57-66.
22. Mao JJ, Nah HD. Growth and development: hereditary and mechanical modulations. *Amer J Orthod Dentofac Orthop* 2004;125:676-689.
23. Singh GD, Callister JD. Use of a maxillary appliance for the resolution of obstructive sleep apnea. *Cranio* 2013;31(3):171-175.